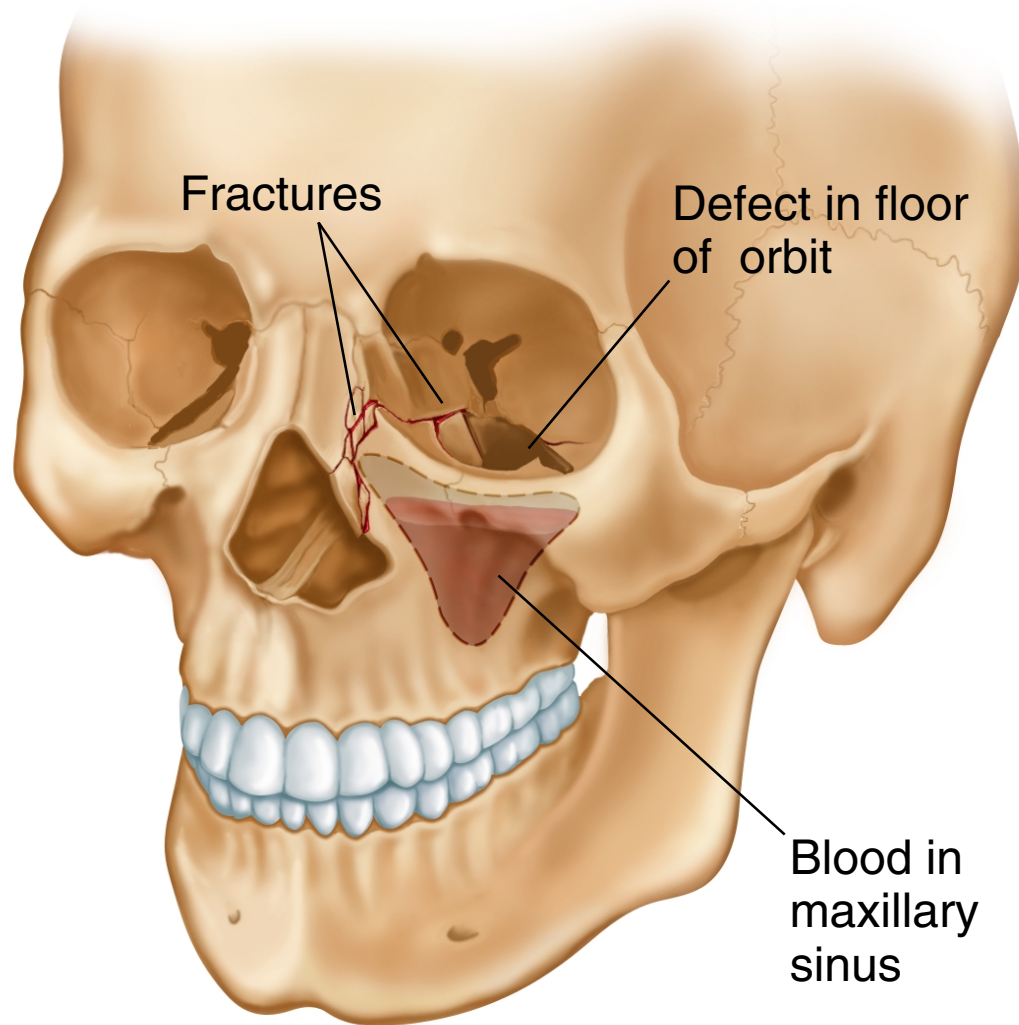
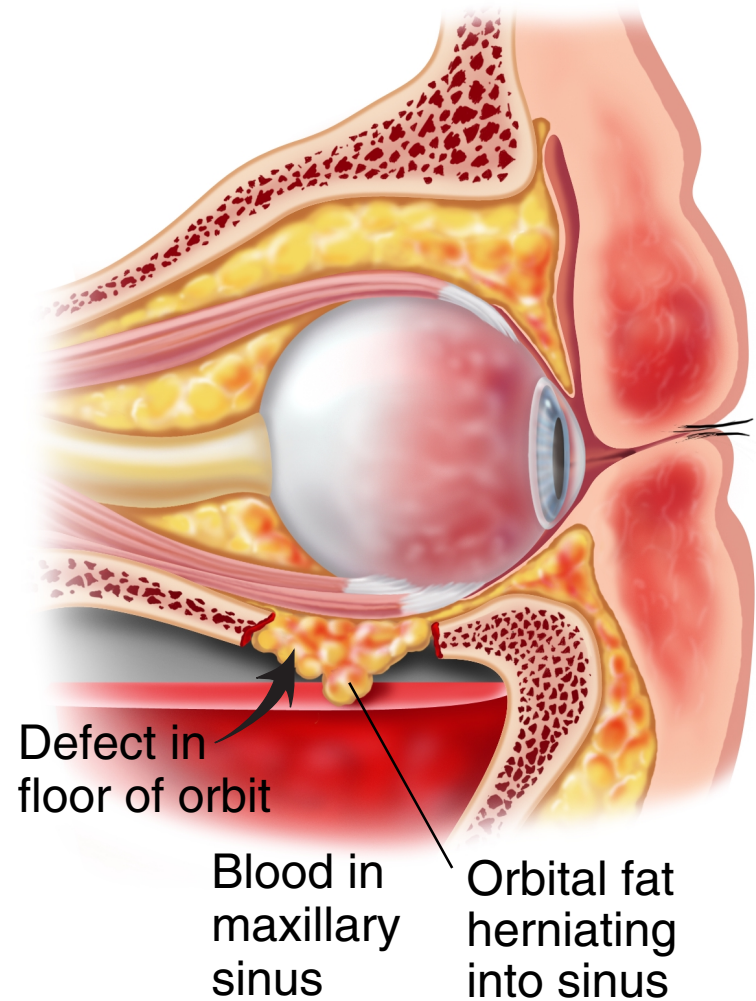


# Blow-Out Fracture of Orbit

8-29-03



**3/4 View of Facial Bones**



**Left Eye - Sagittal View**